Radiotherapie bij slokdarmtumoren :

opvang van nevenwerkingen thuis

Sabine Vanderkam – ZNA – dienst radiotherapie

ESMO Richtlijnen

indicaties radiotherapie

- preoperatieve setting + CT
- primaire behandeling + CT
- palliatieve setting

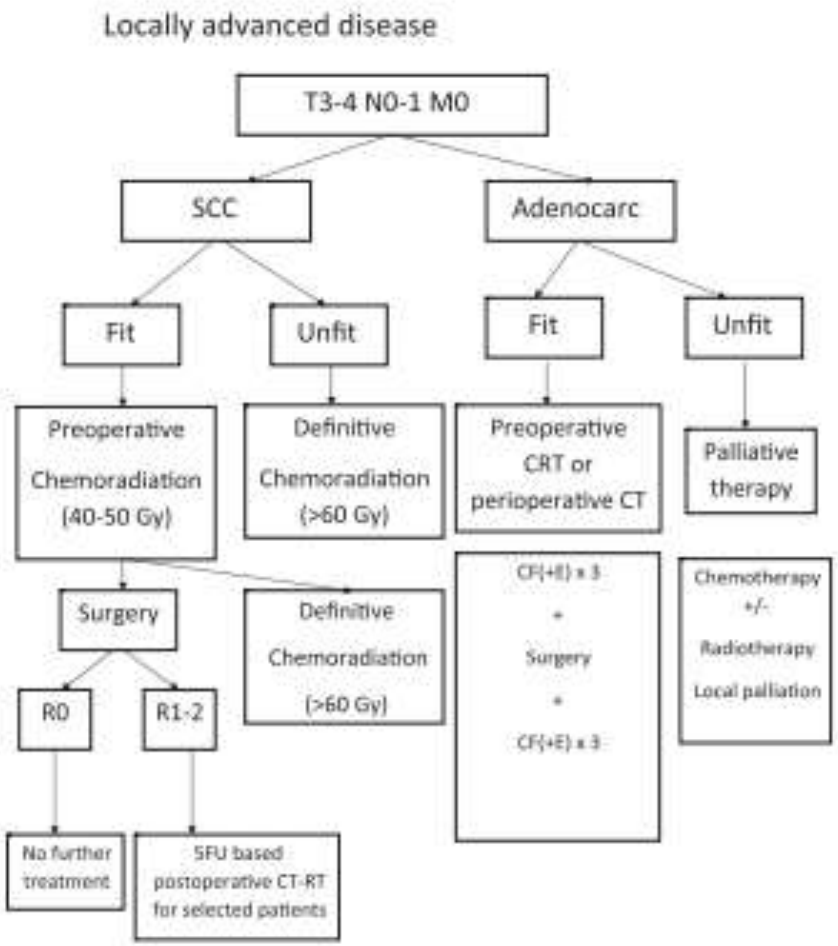

Figure 1. Algorithm for the treatment of esophageal cancer. CT, chemotherapy; RT, radiotherapy; C, cisplatin; F, fluorouracil; E, epirubicin; R0, complete resection; R1–2, incomplete resection.

Preoperatieve RTCT

N ENGL J MED 366;22 NEJM.ORG MAY 31, 2012

ORIGINAL ARTICLE

Preoperative Chemoradiotherapy for Esophageal or Junctional Cancer

P. van Hagen, M.C.C.M. Hulshof, J.J.B. van Lanschot, E.W. Steyerberg,

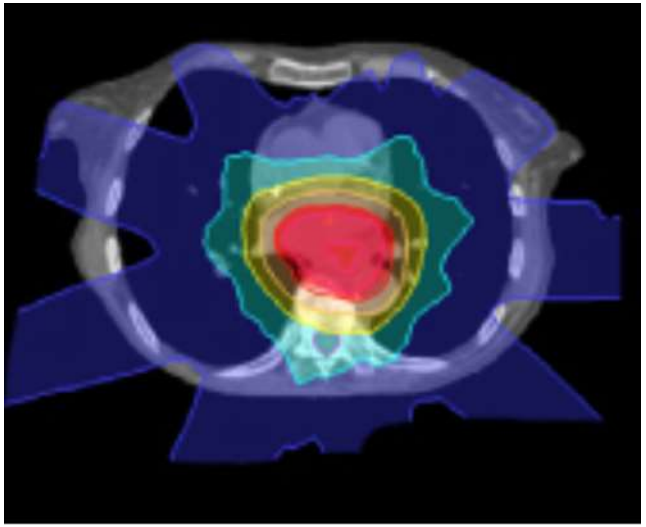

368 patienten – 2004/08
75 % adenocarcinoom – 25% SCC

R → Heelkunde
R → RTCT (41,4 Gy/23#) + carbo/taxol wekelijks -> HK

	Preop CTRT	HK
R0 / pCR	92% / 29%	69%
postop†	4%	4%
Mediane S	49,4 mnd	24 mnd

45 Gy in 25 fracties over 5 weken thv doelvolume (Tumor + LN)
gecombineerd met chemotherapie (carboplatinum / taxol wekelijks)
Immobilisatie mbv longplank (armen boven het hoofd)
gevolgd door recuperatie periode 6 – 8 weken

Toxiciteit CROSS studie

Events tijdens CTRT (# pt /%)	Elke graad	Grade ≥ 3
anorexie	**51pt 30%**	**9pt 5%**
alopecia	25pt 15%	
constipatie	47pt 27%	1pt 1%
diarree	30pt 18%	2pt 1%
Oesophageale perforatie	1pt 1%	1pt 1%
oesophagitis	**32pt 19%**	**2pt 1%**
vermoeidheid	**115pt 67%**	**5pt 2%**
nausea	**91pt 53%**	**2pt 1%**
Neurotoxische effecten	25pt 15%	
braken	**43pt 25%**	**1pt 1%**
leucopenie	103pt 60%	11pt 6%
thrombocytopenie	92pt 54%	1pt 1%

Toxiciteit CROSS studie

Postop event (# pt / %)	CTRT + HK	HK
Pulmonaire complicaties	**78/168 46%**	**82/186 44%**
Cardiale complicaties	**36/168 21%**	**31/186 17%**
Chylothorax	17/168 10%	11/186 6%
mediastinitis	5/168 3%	12/186 6%
Anastomose lek	36/161 22%	48/161 30%
Overlijden - ziekenhuis	6/168 4%	8/186 4%
Overlijden – na 30 dagen	4/168 2%	5/186 3%

pulmonair: pneumonie, atelectase, pneumothorax, pleurale effusie, longembolie en acuut respiratoir falen

cardiaal: arrytmie, AMI, LVF

CROSS studie: resultaten

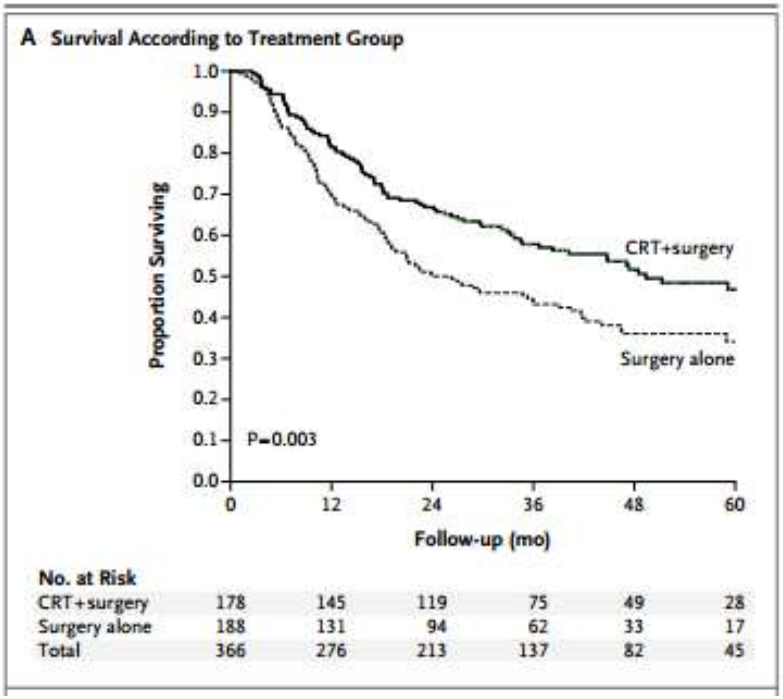

benefit consistent over verschillende subtypes

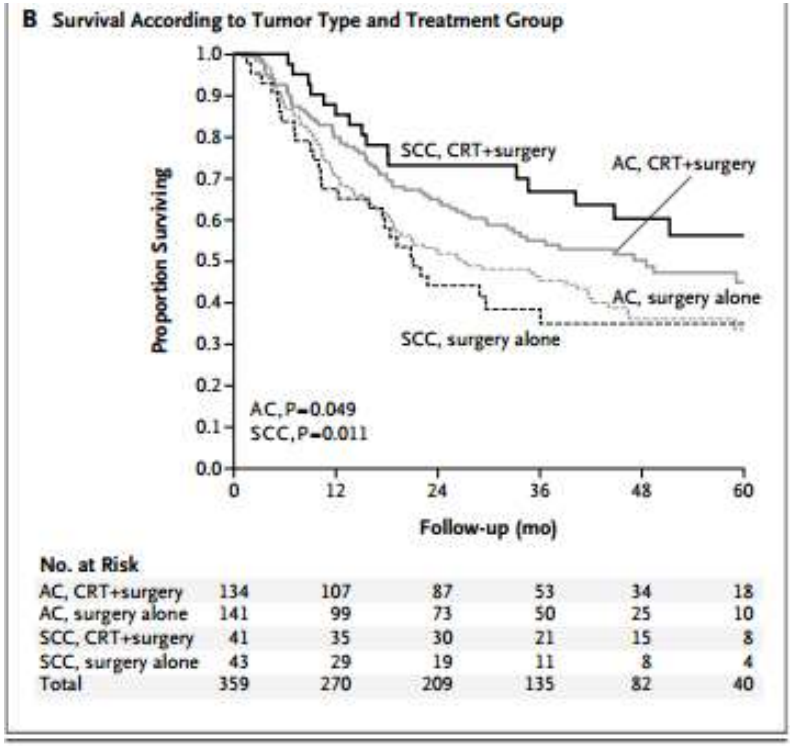

† RTCT 61pt	52pt (85%) PD	9(15%) ICD
† HK 83pt	78pt (94%) PD	4(5%) ICD

Mediane DFS	Niet bereikt RTCT	24.2 mnd HK
Mediane OS	49.4 mnd RTCT	24 mnd HK
OS 1/2/3/5 J	82/67/58/47%	70/50/44/34%

Primaire RTCT

COMBINED CHEMOTHERAPY AND RADIOTHERAPY COMPARED WITH RADIOTHERAPY ALONE IN PATIENTS WITH CANCER OF THE ESOPHAGUS

ARNOLD HERSKOVIC, M.D., KAREN MARTZ, M.S., MUHYI AL-SARRAF, M.D., LAWRENCE LEICHMAN, M.D.,

THE NEW ENGLAND JOURNAL OF MEDICINE Vol. 326 No. 24 June 11, 1992

start 1986 - 1990
HK/RT alleen: mediane S ‹10 mnd – 5 J S 10%

R → RTCT 50 Gy + 4 cycli Cisp/5FU
R → RT 64 Gy

		RTCT	RT
Mediane S		12.5 mnd	8.9 mnd
1jS	2jS	50% -38%	33% -10%

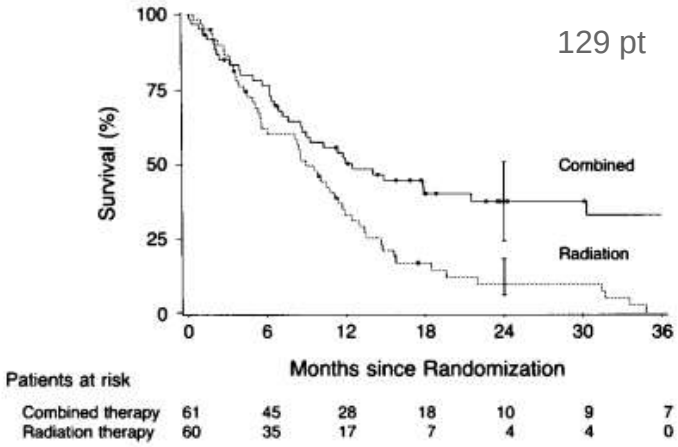

Figure 1. Kaplan–Meier Plot of Survival in Patients with Esophageal Carcinoma Treated with Radiation Alone or with Radiation and Chemotherapy Combined.
Bars indicate 95 percent confidence intervals at 24 months.

	ernstig	levensbedreigend	fataal
RTCT	44%	25%	2 pt
RT	20%	3%	

Palliatieve setting

- EBRT
  - dosis: 30 Gy in 10 fracties – 50 Gy in 25 fracties
  - symptoomcontrole: 70 - 90 % gedurende 3 maanden

- Brachytherapie
  - kortdurende behandeling: 18 Gy in 3 #
  - symptoomcontrole gelijk EB doch betere QoL
  - betere lange termijn effecten op dysfagie
    vergeleken met metalen stent

  → levensexpectantie › 3 mnd

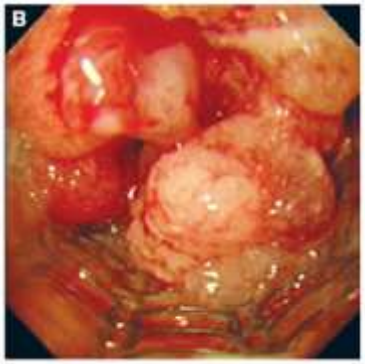

ook hier RT mogelijk

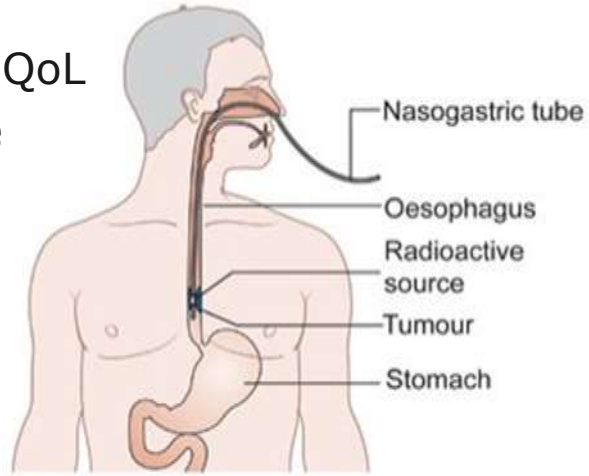

Diagram showing internal radiotherapy for cancer of the oesophagus
Copyright © CancerHelp UK

BIJWERKINGEN RADIOTHERAPIE

"Side effects include, headache, dry mouth, muscle fatigue and turning into a frog."

Acuut

- ✓ voorbijgaand
- ✓ spontaan helend
- ✓ zelflimiterend

<u>voorbeelden :</u>
dermatitis
mucositis
smaakverlies

Laat

- ✓ blijvend
- ✓ complicaties
- ✓ progressief

<u>voorbeelden :</u>
trismus
fibrose/canule
osteoradionecrose

therapeutische index

nutritioneel profiel van de patient

- voedingstoestand wordt beinvloed door mechanische (dysfagie) alsook psychosociale factoren (angst om te eten)
  - meer kauwen, vloeibare voeding
  - malnutritie
  - 70 % ernstig gewichtsverlies (> 10%), snel opkomend (< 4 mnd)

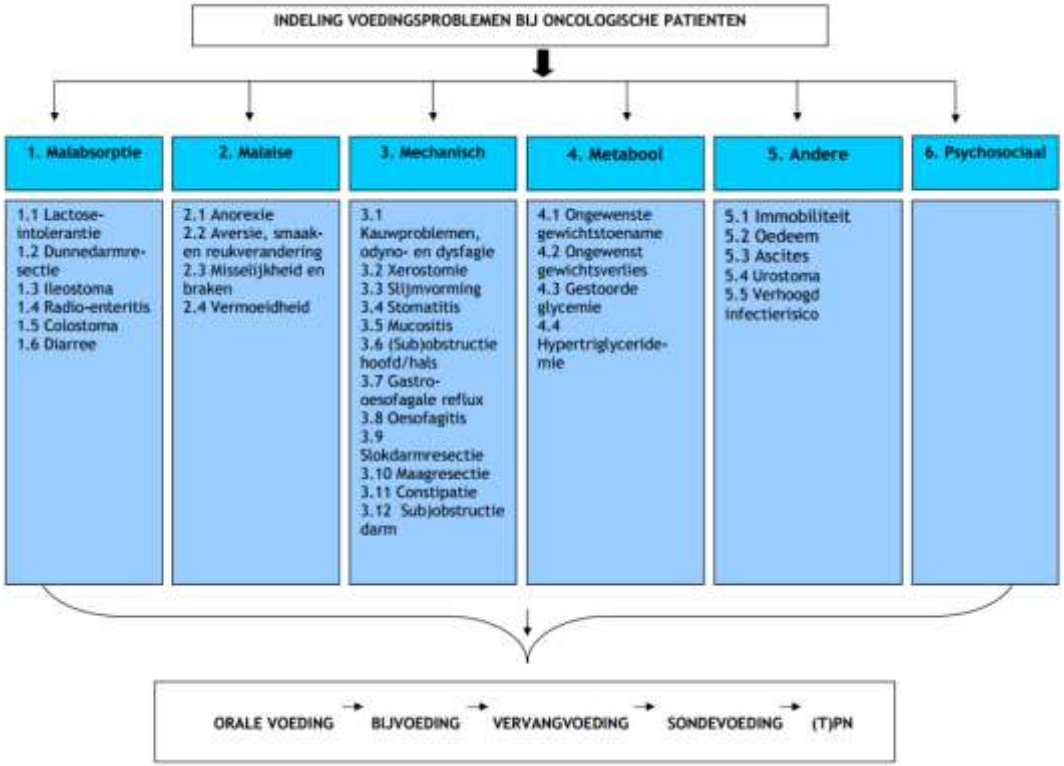

gewichtsverlies slechte prognostische factor voor ziekte uitkomst

Radiatie oesofagitis : acuut

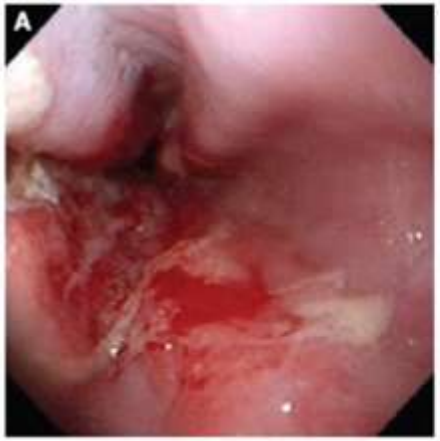

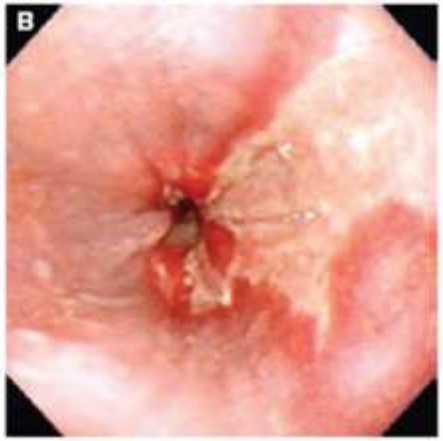

etiologie: effect op de basale epitheliale laag → defect

symptomen: dysfagie, odynofagie en substernaal ongemak

DD candida oesophagitis

endoscopisch: mucositis en ulceratie, zelden perforatie, bloeding

RTOG Acute Morbidity Scoring Criteria [edit]

Organ	Grade 1	Grade 2	Grade 3	Grade 4	Grade 5
Esophagus	Mild dysphagia or odynophagia, Topical anesthetics or NSAIDs, Soft diet	Moderate dysphagia or odynophagia, Narcotic analgesics, Puree or liquid diet	Severe dysphagia or odynophagia, Dehydration or weigh loss >15%, IV fluids, NGT, TPN	Complete obstruction, ulceration, perforation, fistula	Death

Radiatie oesofagitis : behandeling

Symptomatische behandeling

topische anesthetica : vloeibaar lidocaine (®syngel)
analgetica (anti inflammatoire agentia, narcotica)
antacida (protonpomp inhibitie, H2 – antihistaminica)
promotiliteit agentia (metoclopramide (®primperan))

Dieet modicatie

puree, zachte voeding, soep
frequente kleinere maaltijden
geen te koude of te warme maaltijden
vermijden alcohol, roken, koffie, pikante of zure voeding en dranken, chips, krakkers

Therapie van de candida infectie

Radiatie oesofagitis : laat

etiologie: inflammatie, littekenvorming binnen de musculatuur, histologisch ziet men een epitheliale verdikking, chronische inflammatie en submucosale / musculaire fibrose

symptomen:
dysfagie (strictuur of gewijzigde motiliteit, spier of zenuwschade)
chronische ulceratie
fistelvorming

TD5/5 : 60 Gy als 1/3 van slokdarm geincludeerd wordt

RTOG/EORTC Late Morbidity Scoring Schema [edit]

Organ	Grade 1	Grade 2	Grade 3	Grade 4	Grade 5
Esophagus	Mild fibrosis, Slight difficulty swallowing solids, No pain on swallowing	Unable to take solid food normally, Swallowing semi-solid food, Dilatation may be indicated	Severe fibrosis, Able to swallow only liquids, May have pain on swallowing, Dilation required	Necrosis, Perforation, Fistual	Death

Radiatie oesofagitis : behandeling

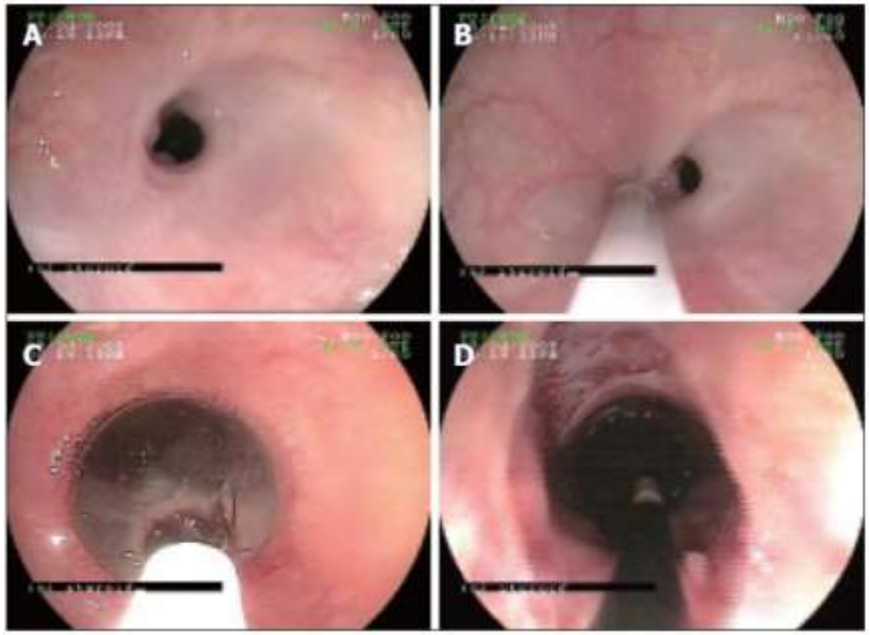

endoscopische dilatatie:
symptoomverbetering
meerdere dilataties noodzakelijk

medicamenteus:
antacida en prokinetische agentia (®metoclopramide) om kans op reflux te verminderen

voedingssonde:
enkel bij extreem gewichtsverlies en patienten die enkel vloeibaar kunnen eten

Endoscopic image of an esophageal stricture and its management. A: A refractory stricture; B: Steroid injection at the proximal edge of the stricture; C: Through-the-scope (TTS) balloon dilation of the stricture; D: The opened stricture after deflation of the TTS balloon.

Radiatie gastritis : acuut

- Symptomen: nausea, braken, dyspepsie, abdominale pijn en malaise
  - symptomen kunnen versterkt worden door CT

- Behandeling
  - anti emetica
  - lichte maaltijd voor RT sessie
  - (niet) – narcotische medicatie
  - antacida, proton pomp inhibitoren

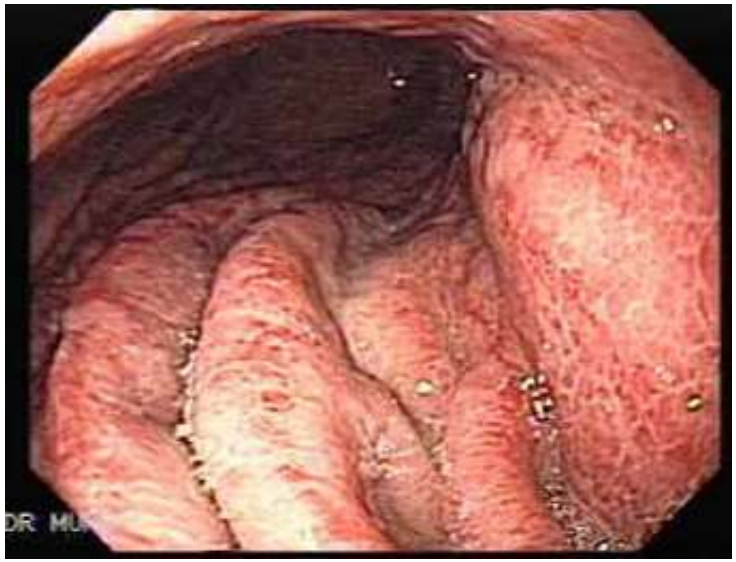

Radiatie gastritis : laat

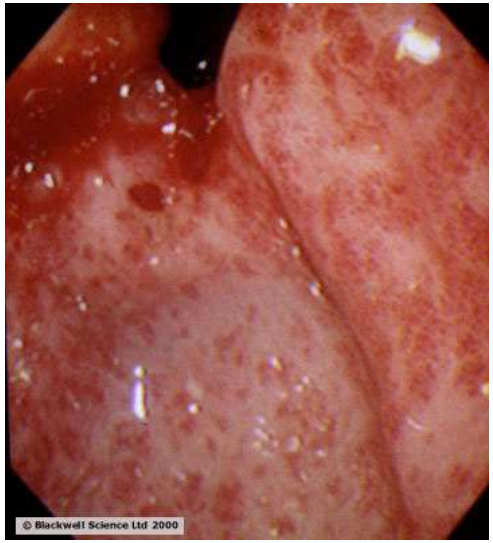

Conspicuous swelling and erythema due to radiation-induced gastritis, with characteristic telangiectasia.

chronische gastritis: verstrijken mucosale plooien, mucosale atrofie, antrale stenose
dyspepsie
late ulceratie

behandeling:
antacida
H2 – antihistaminica
protonpompinhibitoren
sucralfaat

zeldzaam:
ernstige bloeding, ulceratie, gastric outlet obstructie, fistula vorming of perforatie

→ noodzaak chirurgische ingreep

nieuwe RT technieken : OAR

- 4D CT scan dosimetrie
- IMRT techniek / arc therapie

- **Radiatie pneumonitis**
  - **weken / maanden na RT**
  - **respiratoir falen / dood**
  - **→ DVH berekeningen**

gewichtsverlies	5.5%
Opname ziekenhuis	15.7%
voedingssonde	7.4%
Stent plaatsing	4.6%
dilatatie	12%
Radiatie pneumonitis	1.9%
Late RP	5.6%

outcomes of definitive or preoperative IMRT chemoradiation for esophageal cancer, Shirdar R et al, J Radiat oncol 2012:1-8

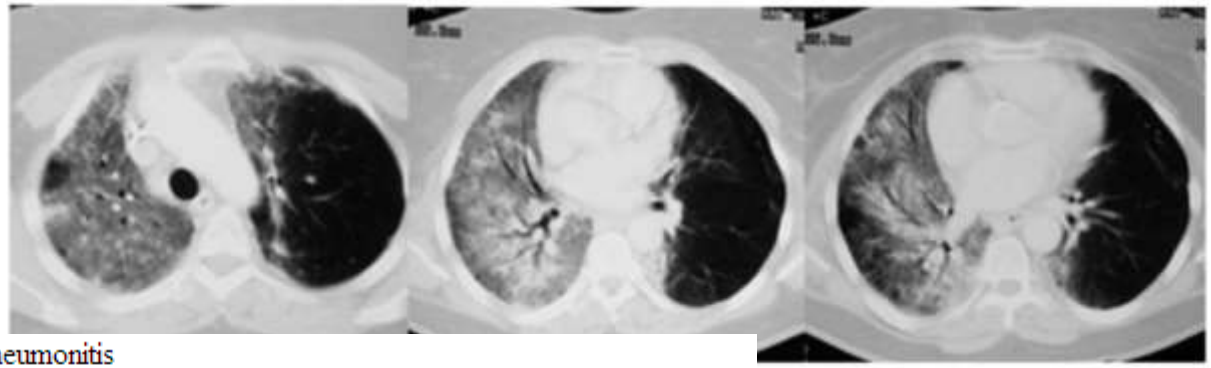

CT findings of acute radiation pneumonitis

- Homogeneous slight increase in attenuation (2-4 months after therapy)
- Patchy consolidation (1-12 months after therapy)
- Non-uniform discrete consolidation (most common; 3 months to 10 years after therapy)

Esophageal Cancer Awareness

nieuwe RT technieken : OAR

- Cardiale toxiciteit
  - pericard effusie / CIHL / AMI

- lever / dundarm / nieren (GEJ tumoren)

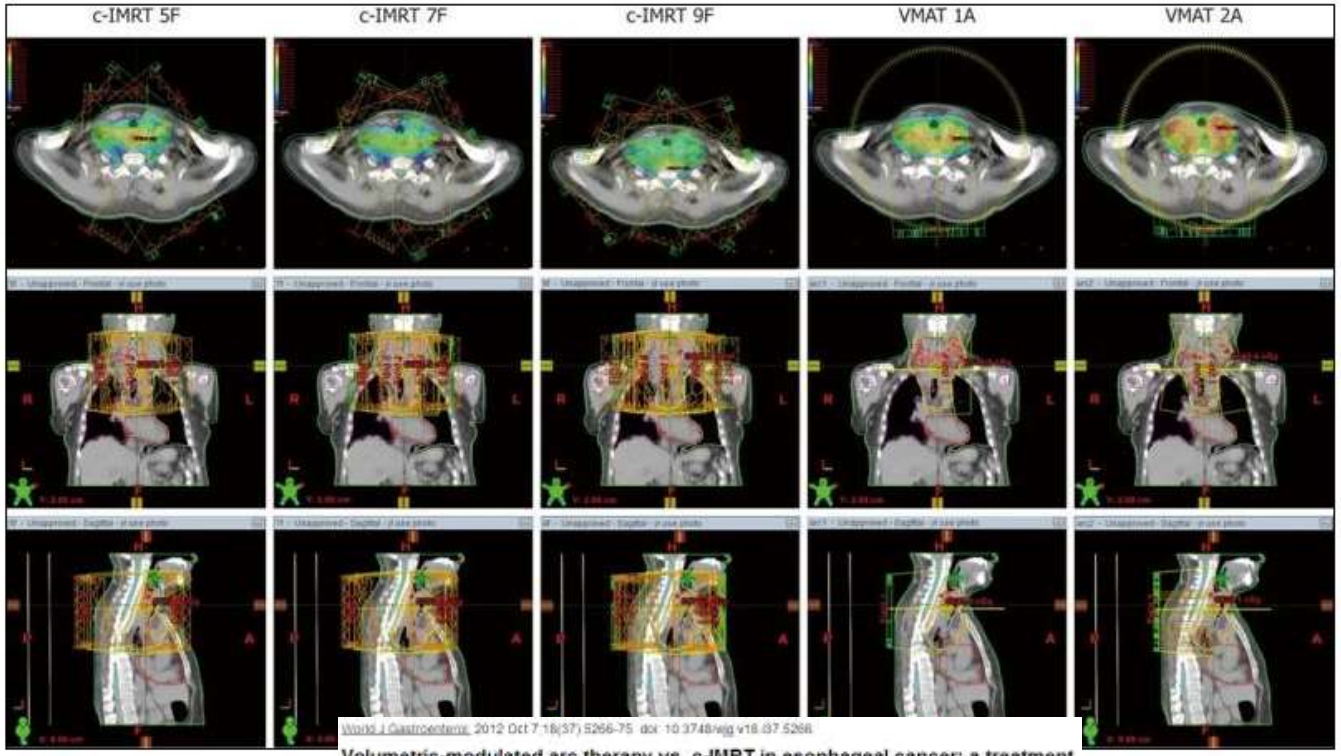

World J Gastroenterol 2012 Oct 7;18(37):5266-75 doi:10.3748/wjg.v18.i37.5266

Volumetric-modulated arc therapy vs. c-IMRT in esophageal cancer: a treatment planning comparison.

Yin L[1], Wu H, Gong J, Geng JH, Jiang F, Shi AH, Yu R, Li YH, Han SK, Xu B, Zhu GY

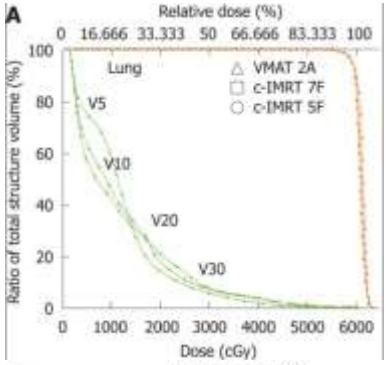

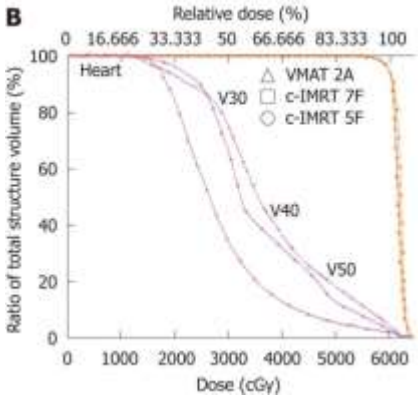

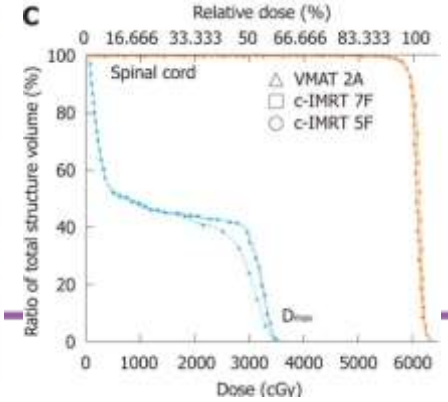

Precise

ZIJN ER NOG

FOKKE & SUKKE
BEZUINIGEN IN HET ZIEKENHUIS
SINDS WE SONDE-VOEDING HEBBEN IN-GEVOERD...
...IS 5 MINUTEN LUNCHPAUZE VOLDOENDE!
RGVT
www.foksuk.nl